

In this article...

- Evidence supporting maggot therapy in wound care
- Indications for use and how the process works
- Patient perception of the treatment

The principles of maggot therapy and its role in contemporary wound care



NT SELF-ASSESSMENT

Test your knowledge.
After reading this article go to nursingtimes.net/NTSAMaggots
If you score 80% or more, you will receive a certificate that you can use as revalidation evidence.

Key points

Maggot therapy has been available on NHS prescription since 2004

Maggots are clinically effective for the debridement of sloughy, necrotic chronic wounds

Secondary benefits of maggot therapy include reduction of wound bacterial load and an acceleration of wound healing

Maggots can be applied clinically directly to the wound or in bagged form and are usually left on a wound for four days before removal

For some patients, there may be associated side-effects of bleeding and pain, and nurses are advised to monitor such patients closely

Author Yamni Nigam is professor (anatomy and physiology), College of Human and Health Sciences, Swansea University.

Abstract Maggot therapy is becoming increasingly established as an option for the debridement and treatment of sloughy, necrotic wounds. Although used tentatively over the previous few decades, it became more widespread following its availability on NHS prescription in 2004. Since then, the scientific and clinical evidence for the efficacy of maggot therapy has mounted considerably, and it has been shown to be effective, not only for wound debridement but also in reducing the bacterial burden of a wound and accelerating wound healing. This article reviews current evidence, and discusses the clinical indications for use, and the rearing and clinical application of maggots, as well as patient and health provider perceptions of maggot therapy.

Citation Nigam Y (2021) The principles of maggot therapy and its role in contemporary wound care. *Nursing Times* [online]; 117: 9, 39-44.

All health professionals are acutely aware of the mounting burden and cost of wound management. The development of non-healing wounds is often an unfortunate and inevitable consequence of the presence of certain chronic conditions, such as chronic obstructive pulmonary disease, cardiovascular disease and diabetes. The underlying pathology of certain conditions, including diabetes, makes it highly probable that the resulting wounds may become necrotic, infected and indolent.

Such wounds can cause severe discomfort and distress to patients. They are often notoriously difficult to treat and tend to harbour antibiotic-resistant strains of bacteria or bacterial biofilm, which can drastically impede healing. Effective wound debridement and a reduction in bacterial burden are an essential part of wound management and, in the search for more effective clinical management, numerous new chronic wound treatment modalities have been introduced over the past two decades.

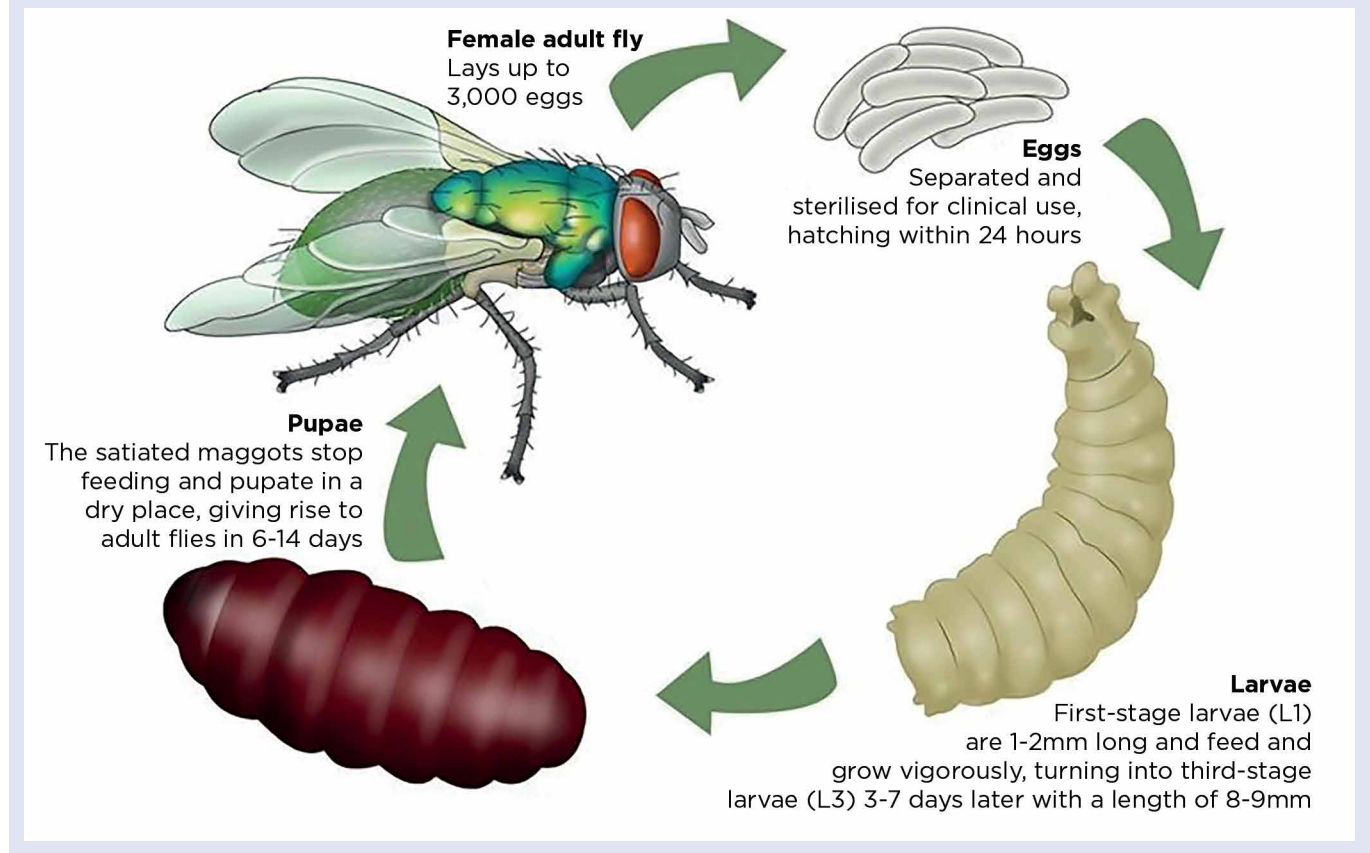
History of maggot therapy

Knowledge of the improvement in the wound state as a consequence of maggot infestation dates back centuries, but documented evidence is mainly through military records. It was Dr William Baer who wrote about the positive effects and outcomes of unintentional maggot infestation on open battlefield wounds inflicted on soldiers in the First World War (Manning and Calhoun, 2011). After the war, in his role as professor of orthopaedic surgery at John Hopkins School of Medicine, in the US, he initiated the use of sterile maggots as a reputable method of wound therapy. His pioneering work meant the use of maggot therapy began to flourish in the 1930s and early 1940s, and was widely used in hospitals in the US and Canada.

By the mid-1940s, following the first clinical use of penicillin, the industrial antibiotic era commenced in earnest; this ended the use of maggots as the steady and consistent overuse of antibiotics progressed. Over time, several species and strains of bacteria emerged that were

Clinical Practice Review

Fig 1. Life cycle of the medicinal maggot, *Lucilia sericata*



slowly becoming more and more resistant to almost any antibiotic therapy. We now face a global public-health crisis, with a worldwide rise in patients with antibiotic-resistant wound infections (Alfadli et al, 2018). Consequently, maggot therapy is being revisited and advocated for debridement, disinfection and the ultimate healing of necrotic tissue.

Currently, there are several specialist laboratories worldwide that are licensed to aseptically produce clinical-grade maggots. 'Medicinal maggots' can be ordered through these companies and supplied directly to hospitals and clinical centres for the treatment of all sorts of wounds, including leg ulcers, pressure ulcers, and diabetic and necrotic ulcers, as well as infected surgical wounds, burns and trauma injuries.

What is maggot therapy?

Maggot therapy, also known as larval therapy, is one option available for treating chronic, infected, necrotic and sloughy wounds. The maggots used are special clinical-grade, aseptically reared larvae of the common greenbottle fly (*Lucilia sericata*). Fig 1 outlines the life cycle of this medicinal maggot.

For clinical use, disinfected eggs hatch under sterile conditions. Upon emerging, and just prior to being packaged for delivery, hungry first-stage (L1) larvae are fed once on a high-protein cereal-based diet, so they can survive for up to 24 hours in transit. Once placed on a wound, the larvae can feed and grow to their final third stage (L3); they usually remain on the wound for four days before being removed. Used larvae are treated as infectious clinical waste.

If a wound is assessed as suitable for treatment with maggots, the therapy can progress under clinical guidance. Suitable wounds include any type of chronic wound that has moist slough or necrotic tissue on its floor (Naik and Harding, 2017). The application of maggots requires appropriately trained clinicians to place a number of tiny larvae onto a wound, either as free-range or bagged maggots.

Over the next few days, the larvae not only clear away the dead, sloughy or necrotic tissue in the wound, but also eliminate infection. Once the larvae are removed, the wound is reassessed for further therapy. Maggots are now thought to benefit wounds in three ways:

- Debridement (getting rid of dead tissue);

- Disinfection (reducing bacterial infection and biofilm burden);
- Helping to accelerate wound healing.

Advances in our understanding of maggot therapy and its treatment stem from clinical reports and the results of laboratory investigations in these three areas.

Wound debridement

The primary goal of maggot therapy is to carry out the process of wound debridement. The ability of *L. sericata* larvae to achieve speedy and effective debridement is attributed to their highly necrophagous nature (ability to rapidly consume and ingest dead tissue).

Clinical evidence base

The efficacy of maggot therapy in wound debridement is proven. Since its resurgence in the US and UK in the 1990s, clinical studies have assessed the success of larval therapy compared with conventional treatment methods for debriding chronic wounds (Dumville et al, 2009a; Opletalová et al, 2012).

Sun et al's (2014) systematic review of clinical studies from 2000-2014 incorporated 12 comparative studies, including six randomised controlled trials. Based on an

analysis of these 12 studies, the authors concluded that larval therapy was more effective and more efficient in the debridement of chronic ulcers compared with conventional treatments (Sun et al, 2014). As an example, one randomised controlled trial compared the clinical effectiveness of a larval therapy dressing with a standard debridement technique (hydrogel) on venous or mixed arterial/venous leg ulcers. The analysis revealed that 96.9% of ulcers were debrided in the larvae arm compared with only 34.4% from the hydrogel arm (Mudge et al, 2014).

Sun et al (2014) also noted other benefits of associated larval therapy that had been identified in the studies – namely, a quicker healing rate of chronic wounds (Sherman et al, 2003), a longer antibiotic-free time period and decreased amputation risk (Armstrong et al, 2005). In addition, an increasing number of reports show maggot therapy success from controlled, retrospective studies and clinical case studies (Sherman, 2014).

Scientific evidence base

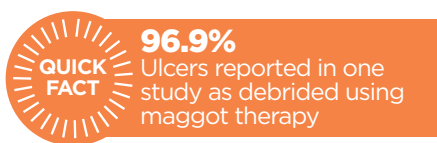
Wound debridement is the best understood aspect of maggot therapy. It is now known that maggots produce a combination of proteolytic and other digestive enzymes that are released externally in their secretions and get distributed over the wound as the maggot crawls around (Thomas et al, 2002). Maggot movement over the surface tissue facilitates the penetration of these enzymes into the necrotic tissue, causing it to break down and liquefy into a nutrient-rich fluid that the larvae subsequently ingest. Two key enzymes, trypsin and chymotrypsin, have been identified as being produced by medicinal maggots (Chambers et al, 2003), with studies suggesting that key to their effectiveness is the ability of these enzymes to withstand endogenous wound inhibitors that would normally degrade and destroy other enzymes (Telford et al, 2011).

Larval chymotrypsin has been shown to effectively degrade macromolecules present in venous leg ulcer slough and large molecules, such as fibrin and fibrinogen, that, if left on the wound, could act as key substrate sites for the accumulation and attachment of wound bacterial biofilm (Pritchard and Brown, 2015). More recently, a maggot enzyme known as 'Jonahm' was found to be active in digesting certain extracellular matrix components normally present in the chronic wound environment (Pöppel et al, 2016). This points towards the debridement effect of larval

secretions being caused by a complex mix of enzymes.

Bacterial burden

While debridement is often the primary aim in the clinical use of maggot therapy, evidence is accumulating that the therapy contributes to other aspects of wound treatment (Pritchard and Nigam, 2013). In particular, larvae have been shown to have a significant antibacterial effect on the wound surface, not only by the removal of infected tissue, but also through the antimicrobial action of their secretions (Valachová et al, 2013; Bexfield et al, 2008).



The explanation for the observed antimicrobial activity of maggot secretions is that it would be vital for any organism inhabiting a heavily contaminated environment. In their natural environment, blowfly larvae are exposed to decaying carrion and masses of heavily contaminated materials so need to be able to survive this.

With regards to chronic wounds, bacterial infection can both compromise and delay wound healing (Roy et al, 2020). Progression of healing is said to be dependent on both bacterial count and the microbial species present, so managing the bacterial levels of the wound site is vital for healing (Negut et al, 2018). Recently, there has been particular interest in understanding and identifying the therapeutic antimicrobial properties of maggot secretions, the main drive for this being the use of larvae as a source of novel antibiotics and anti-infectives (Pöppel et al, 2015).

Most of the compelling discoveries on the nature of the therapeutic antimicrobial effects have come from scientific laboratory findings using externalised maggot secretions. Several studies – for example, those by Jaklic et al (2008) and Daeschlein et al (2007) – have served to reaffirm the notion that maggot secretions are effective in destroying a broad range of gram-positive and gram-negative bacteria.

Clinical evidence from a recent randomised controlled trial of 50 patients with diabetic foot ulcers by Malekian et al (2019) also supports this theory. Patients were randomly selected for two groups: a control group treated conventionally with surgical debridement, antibiotic therapy and offloading; and a treatment group that

also received maggot therapy. A swab culture was collected before and after each maggot application and analysed for the presence of *Staphylococcus aureus* and *Pseudomonas aeruginosa*. In the maggot treatment group, cases of *S aureus* infection reduced after 48 hours of treatment, with a further reduction after a second application of larvae. Cases of *P aeruginosa* reduced too, but only after a second maggot treatment. In the control group, which had no maggot therapy, no reduction in cases of either *S aureus* or *P aeruginosa* was observed (Malekian et al, 2019).

The formation of bacterial biofilm on a wound can also pose a serious problem to wound healing. Biofilms are widely recognised to be highly resistant to antibiotics and host immunity. Maggots, however, have been shown to be able to tackle bacteria in this more-resistant form, and various studies have determined the positive effect of maggot secretions, both on the ability of bacteria to form biofilm communities and as an agent to disrupt existing bacterial biofilms (Harris et al, 2013).

Maggot therapy and wound healing

For years, anecdotal reports from wound clinicians have suggested wounds treated with maggots had better outcomes and healed faster compared with those not treated with maggots. It is only recently, however, that these healing effects have been scientifically and clinically investigated. There is now growing evidence supporting maggot-induced acceleration of healing. This includes the ability of maggots to:

- Promote angiogenesis (growth of new blood vessels);
- Improve oxygen perfusion to wound sites;
- Enhance the migration of vital cells (fibroblasts) to the wound bed (Nigam and Morgan, 2016).

A recent review of clinical studies from 2000-2015 by Siribumrungwong et al (2018) compared time to heal in five separate studies; the authors reported that time to heal for maggot-treated wounds was shorter (3.1 weeks) than conventionally treated wounds.

Indications and clinical use

Currently, maggot therapy is a treatment of last resort, usually used only when other conventional therapies fail or when non-surgical debridement is being considered. The National Institute of Health and Care Excellence (2014) suggests considering

Clinical Practice Review

maggot therapy in chronic pressure ulcers if debridement is needed, but sharp debridement is contraindicated. Maggots have been available on NHS prescription since 2004. In the US, they are classed as medical devices, making them the first live organism marketed in the US for medical purposes, with treatment being reimbursable by medical insurers.

Most moist wounds that possess a degree of devitalised, sloughy tissue are suitable for maggot therapy, but published reports have shown successful outcomes when using it for other clinical manifestations (Borst et al, 2014) and conditions including haematomas (Rafter, 2012).

Rearing of clinical-grade maggots

Even though the efficacy of larval therapy is well established, its widespread adoption is limited by several issues, including practical problems associated with the use of living organisms. These include a short shelf life, the need for an advanced logistic network to allow for express delivery, and training to ensure that maggot dressings are applied and maintained correctly. While clinical grade maggot-rearing facilities have been established all over the world, in the UK there is only one company specialising in the sterile production of medicinal maggots. Based in South Wales, it is the sole provider of larvae to the UK and several other countries in Europe.

Application and management

Maggot therapy is undertaken under clinical control and direction. Currently, there are two methods of larval application: free range (Fig 2) and bagged (Fig 3).

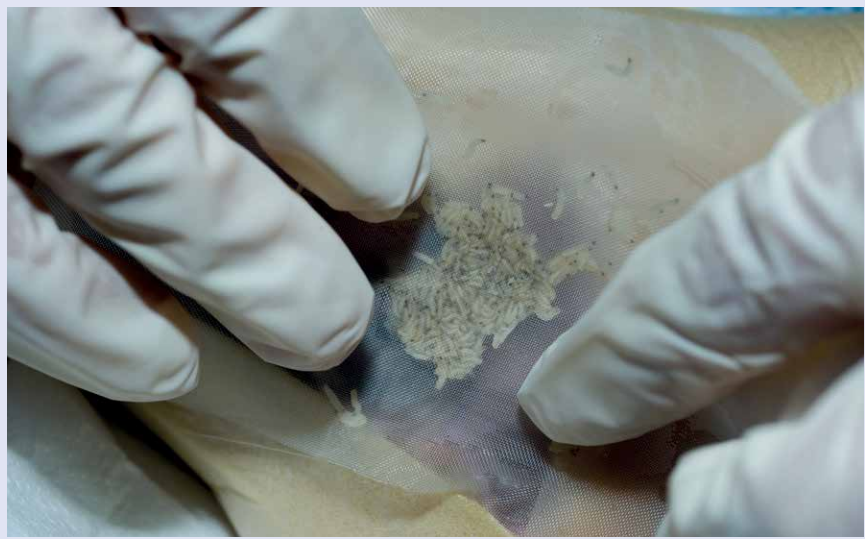Free-range maggots

Free-range maggots are applied directly onto the wound. They arrive in a sterile tube and, with the help of a small pod of sterile saline, can be gently poured directly onto the wound. The wound is then well sealed with a breathable dressing. Essentially the maggots are free to roam within the confines of the wound bed and are able to reach all corners of the enclosed wound space. The use of free-range larvae dominated clinical use for decades, before the development of the maggot bag.

Bagged maggots

Bagged maggots became available in the UK in 2002. Larvae are enclosed between two layers of thin polyvinyl netting; a small cube of spacer material is inserted to prevent bag collapse, and the bag edges are heat sealed (Fig 3a) ready to be sent out for delivery.

Fig 2. Application of free-range maggots onto a wound



“Recently, there has been particular interest in understanding and identifying the therapeutic antimicrobial properties of maggot secretions”

The bag containing the maggots (BioBag) is placed easily on the wound. Some netting is placed over the bag and taped to an adhesive on the wound edges. Wet gauze and a light bandage are wrapped over the net. Maggot bags come in varying sizes to match different wound sizes. The larvae remain sealed inside the bag throughout the whole treatment period. It is the necrophagous nature of larvae that has enabled the development of the maggot bag; as maggots have no teeth, they release digestive enzymes through the netting, turning the dead and devitalised tissue into a sort of ‘soup’ they can then ingest.

BioBags or free-range larvae remain on the wound for three to seven days per application. During this time, the tiny L1 larvae become larger L3 larvae (Fig 3b), and any maggot dressings should then be removed and treated as contaminated waste. The number of fresh maggot therapy applications required for complete wound debridement depends on the type of wound, but usually ranges from one to three treatments.

Adverse effects

There may be side-effects of maggot therapy in some patients, including bleeding and pain.

Bleeding

Maggot therapy should be used cautiously and under close supervision near exposed blood vessels, organs or wounds in body cavities. As maggots are also known to produce an anticoagulant (Van der Plas et al, 2014), bleeding complications have been encountered, so observation of the therapy is required, particularly for patients who are on anticoagulant therapy or have bleeding tendencies.

Pain

The skin around a wound may be sensitive to motion, pressure and the liquefied necrotic drainage associated with maggot secretions. The use of protective creams can prevent this last from making contact with healthy periwound skin. The sensation of maggot movement becomes more apparent after 24 hours of therapy, due to the increased larval size (Jordan et al, 2018).

The associated side-effect of pain is reported in approximately 5-30% of patients and ranges from localised tissue discomfort to significant pain, although most of these patients report baseline pain before maggot therapy administration (Jordan et al, 2018). Most complaints of pain can be treated with analgesics and some clinicians suggest that pre-emptive analgesia may be helpful, particularly when treating patients with a known pre-disposition for pain exacerbations.

Perception of maggots

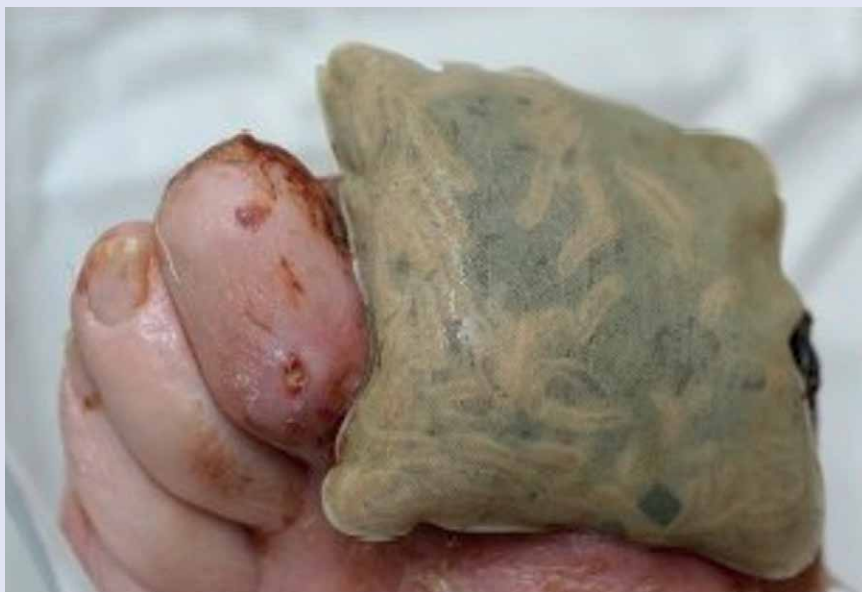Anecdotal reports suggest the potential benefits of maggot therapy are overshadowed by the ‘yuck factor’ (an inherently negative, cultural dislike of maggots). A

Clinical Practice Review

Fig 3. Sealed maggot BioBag



3a. BioBag pre-application



3b. Maggot bag after three days' application

2009b). For patients with a chronic wound, the offer of maggot therapy is often their final hope, but Steenvoorde et al (2005) found a high number of patients are subject to adverse social interactions while undertaking it. This consisted mainly of other people finding the idea of maggot therapy “eerie”. The authors suggested:

- Public acceptance is important to reduce worry and keep patients’ adverse feelings to a minimum;
- There is a need to decrease the general prejudice towards maggot therapy.

To help with this, in 2016 at Swansea University, we set up a worldwide public engagement campaign, Love a Maggot! (loveamaggot.com), which addresses the perception of the general public towards maggot therapy.

Cost

The cost of an initial maggot treatment will vary depending on how many maggots are needed or the size of the BioBag required. The smallest maggot bag costs approximately £250.00, and this is a crucial factor when considering whether to embark on this therapy or not. However, reports suggest that using maggots is, in fact, a very cost-effective wound treatment (Bennett et al, 2013; Wayman et al, 2000).

Clinician acceptance

Anxiety about the use of maggots is also common among health providers (Jones et al, 2011; Dumville et al, 2009b). In the UK, wound care is predominantly nurse led. Sherman (2009) showed that health professionals and administrators are much more likely to be repulsed by the thought of maggot dressings than the patient with the chronic wound.

We conducted a UK survey through *Nursing Times* that suggested not all nurses are keen on maggot therapy (Stephenson, 2017). A paper on the study of which the survey was a part is still in submission, but the results showed that wound specialist nurses rated maggot therapy highly, and were less squeamish and felt less revulsion than non-wound specialist nurses. This suggests a need for better education and training for all nurses as, if general team/ward nurses are unwilling to help and support the ongoing therapy, it may inhibit the ability of specialist nurses to offer this treatment to patients who might benefit from it.

The future of maggot therapy

During the last decade, thousands of patients all over the world have had their

study undertaken by Nigam et al (in press), surveyed and evaluated public perceptions and understanding, along with the acceptance, of maggot therapy. This revealed some worries and fears, with only 36% of survey participants agreeing that they would accept maggot therapy as a first choice for a hypothetical painful wound; this proportion did, however, increase with wound severity.

The most predominant concerns about maggot therapy were:

- Sensation;
- A feeling of disgust.

Influential factors for this negativity included:

- A lack of information and understanding about the therapy;
- Associated fears about maggots.

Patient views

Some patients may express anxiety when maggot therapy is suggested and applied, but patients are generally considered very accepting, as they have often suffered with a non-healing stagnant wound for many months or years and are quite desperate for some improvement (Dumville et al,

Clinical Practice Review

Box 1. Clinical case study

A 58-year-old woman, who was fit and well but had a medical history of diabetes and high blood pressure, presented to the emergency department with acute abdominal pain and was diagnosed with a colon abscess. She was admitted in January for computed tomography image-guided drainage, which failed several times and, in February, underwent surgical drainage through a midline incision. Two days after surgery, the wound dehiscence (burst open), so tension sutures were placed intraoperatively and then removed three weeks later. Unfortunately, the wound dehiscence again shortly afterwards and the patient was referred to the tissue viability service. Sharp debridement was contraindicated due to sutures being visible.

The wound was thick, with tenacious slough and the tissue viability nurse chose to treat with maggot therapy to avoid the need for invasive surgery. The wound was treated with one BB300 BioBag dressing, with three applications of larval therapy used over 14 days. The patient was aware that the larvae were present on her wound but did not experience any issues from pain or discomfort.

After three rounds of treatment, the wound bed was left with 100% granulation tissue. The wound had progressed from complete slough coverage to healthy granulation tissue and wound margin contraction. Following the successful debridement of the wound, negative pressure wound therapy was started to maintain the momentum of wound progression and promote wound closure.

In April the patient was discharged. The wound continued to close and was well healed by the end of October.

- Negut I et al** (2018) Treatment strategies for infected wounds. *Molecules*; 23: 9, 2392.
- Nigam Y et al** (in press) An exploration of public perceptions and attitudes towards maggot therapy. *Journal of Wound Care*.
- Nigam Y, Morgan C** (2016) Does maggot therapy promote wound healing? The clinical and cellular evidence. *Journal of the European Academy of Dermatology and Venereology*; 30: 5, 776-782.
- Opletalová K et al** (2012) Maggot therapy for wound debridement: a randomized multicenter trial. *Archives of Dermatology*; 148: 4, 432-438.
- Pöppel A-K et al** (2016) A Jonah-like chymotrypsin from the therapeutic maggot *Lucilia sericata* plays a role in wound debridement and coagulation. *Insect Biochemistry and Molecular Biology*; 70: 138-147.
- Pöppel A-K et al** (2015) Antimicrobial peptides expressed in medicinal maggots of the blow fly *Lucilia sericata* show combinatorial activity against bacteria. *Antimicrobial Agents and Chemotherapy*; 59: 5, 2508-2514.
- Pritchard DI, Brown AP** (2015) Degradation of MSCRAMM target macromolecules in VLU slough by *Lucilia sericata* chymotrypsin 1 (ISP) persists in the presence of tissue gelatinase activity. *International Wound Journal*; 12: 4, 414-421.
- Pritchard DI, Nigam Y** (2013) Maximising the secondary beneficial effects of larval debridement therapy. *Journal of Wound Care*; 22: 11, 610-616.
- Rafter L** (2012) Debridement of a traumatic haematoma using larval therapy. *Wounds UK*; 8: 1, 81-88.
- Roy S et al** (2020) *Staphylococcus aureus* biofilm infection compromises wound healing by causing deficiencies in granulation tissue collagen. *Annals of Surgery*; 271: 6, 1174-1185.
- Sherman RA** (2014) Mechanisms of maggot-induced wound healing: what do we know, and where do we go from here? *Evidence-based Complementary and Alternative Medicine*; 2014: 592419.
- Sherman RA** (2009) Maggot therapy takes us back to the future of wound care: new and improved maggot therapy for the 21st century. *Journal of Diabetes Science and Technology*; 3: 2, 336-344.
- Sherman RA** (2003) Maggot therapy for treating diabetic foot ulcers unresponsive to conventional therapy. *Diabetes Care*; 26: 2, 446-451.
- Siribumrungwong B et al** (2018) Maggot therapy in angiopathic leg ulcers: a systematic review and meta-analysis. *The International Journal of Lower Extremity Wounds*; 17: 4, 227-235.
- Steenvoorde P et al** (2005) Maggot therapy and the "yuk" factor: an issue for the patient? *Wound Repair and Regeneration*; 13: 3, 350-352.
- Stephenson J** (2017) Nurses asked for views on use of maggots in wound care. *nursingtimes.net*, 27 November.
- Sun X et al** (2014) A systematic review of maggot debridement therapy for chronically infected wounds and ulcers. *International Journal of Infectious Diseases*; 25: 32-37.
- Telford G et al** (2011) Maggot chymotrypsin I from *Lucilia sericata* is resistant to endogenous wound protease inhibitors. *British Journal of Dermatology*; 164: 1, 192-196.
- Thomas S et al** (2002) The effect of containment on the properties of sterile maggots. *British Journal of Nursing*; 11: 12 Suppl, S21-S28.
- Valachová I et al** (2013) Expression of lucifensin in *Lucilia sericata* medicinal maggots in infected environments. *Cell and Tissue Research*; 353: 1, 165-171.
- Van der Plas MJA et al** (2014) A novel serine protease secreted by medicinal maggots enhances plasminogen activator-induced fibrinolysis. *PLoS One*; 9: 3, e92096.
- Wayman J et al** (2000) The cost effectiveness of larval therapy in venous ulcers. *Journal of Tissue Viability*; 10: 3, 91-94.

wounds successfully treated with maggots, as illustrated in the case study (Box 1). Maggot therapy is recognised by many clinicians as an important treatment in its own right or as an adjunct to conventional wound-care therapies. Wound care professionals are constantly searching for a dressing and/or medical device that will selectively debride necrotic tissue, decrease the bacterial burden of a wound, prevent or remove bacterial biofilm and promote the growth of healthy new tissue. The mounting evidence from scientific, published investigations, randomised controlled trials, successful clinical studies and case studies, indicates that maggot therapy may come very close to addressing all of these factors. **NT**

References

- Alfadli M et al** (2018) Risk factors and distribution of MDROs among patients with healthcare associated burn wound infection. *Germes*; 8: 4, 199-206.
- Armstrong DG et al** (2005) Maggot therapy in "lower-extremity hospice" wound care: fewer amputations and more antibiotic-free days. *Journal of the American Podiatric Medical Association*; 95: 3, 254-257.
- Bennett H et al** (2013) Cost-effectiveness of interventions for chronic wound debridement: an evaluation in search of data. *Wounds UK*; 9: 4 (Suppl), 3-11.
- Bexfield A et al** (2008) The antibacterial activity against MRSA strains and other bacteria of a <500Da fraction from maggot excretions/secretions of *Lucilia sericata* (Diptera: Calliphoridae). *Microbes and Infection*; 10: 4, 325-333.
- Borst GM et al** (2014) Maggot therapy for elephantiasis nostras verrucosa reveals new applications and new complications: a case report. *The International Journal of Lower Extremity Wounds*; 13: 2, 135-139.
- Chambers L et al** (2003) Degradation of extracellular matrix components by defined proteinases from the greenbottle larva *Lucilia sericata* used for the clinical debridement of non-healing wounds. *British Journal of Dermatology*; 148:1, 14-23.
- Daeschlein G et al** (2007) In vitro antibacterial activity of *Lucilia sericata* maggot secretions. *Skin Pharmacology and Physiology*; 20: 2, 112-115.
- Dumville JC et al** (2009a) Larval therapy for leg ulcers (VenUS II): randomised controlled trial. *BMJ*; 338: b773.
- Dumville JC et al** (2009b) VenuS II: a randomised controlled trial of larval therapy in the management of leg ulcers. *Health Technology Assessment*; 13: 55, 1-182.
- Harris LG et al** (2013) *Lucilia sericata* chymotrypsin disrupts protein adhesin-mediated staphylococcal biofilm formation. *Applied and Environmental Microbiology*; 79: 4, 1393-1395.
- Jaklič D et al** (2008) Selective antimicrobial activity of maggots against pathogenic bacteria. *Journal of Medical Microbiology*; 57: 5, 617-625.
- Jones J et al** (2011) Maggots and their role in wound care. *British Journal of Community Nursing*; 16: Sup3, S24-S33.
- Jordan A et al** (2018) Maggot debridement therapy: a practical review. *International Journal of Academic Medicine*; 4: 1, 21-34.
- Malekian A et al** (2019) Efficacy of maggot therapy on *Staphylococcus aureus* and *Pseudomonas aeruginosa* in diabetic foot ulcers: a randomized controlled trial. *Journal of Wound, Ostomy and Continence Nursing*; 46: 1, 25-29.
- Manring MM, Calhoun JH** (2011) Biographical sketch: William S. Baer (1872-1931). *Clinical Orthopaedics and Related Research*; 469: 4, 917-919.
- Mudge E et al** (2014) A randomized controlled trial of larval therapy for the debridement of leg ulcers: results of a multicenter, randomized, controlled, open, observer blind, parallel group study. *Wound Repair and Regeneration*; 22: 1, 43-51.
- Naik G, Harding KG** (2017) Maggot debridement therapy: the current perspectives. *Chronic Wound Care Management and Research*; 4: 121-128.
- National Institute of Health and Care Excellence** (2014) *Pressure Ulcers: Prevention and Management*. NICE.